

Bioaccumulation and Evaluation of Magnesium Oxide Nanoparticles Toxicity and Combination Effects of Vitamin E and C with it on Exposed Male Rats

Soma Ismaeel Majeed¹ Sulaf Mustafa Mohammed¹ Ali Mustafa Mohammad²

¹Department of Biology, College of Science, University of Sulaimani, Sulaimani, Iraq

²Department of Physics, College of Education, University of Garmian, Kalar, Iraq

<https://doi.org/10.24017/Science.2023.1.1>

Revised: September 12, 2022 | Accepted: November 11, 2022 | Available Online: February 03, 2023

ABSTRACT

In the recent years, MgO nanoparticles (MgO NPs) have been one of the metal oxide nanoparticles that used in various medicinal fields. Despite MgO NPs' widespread use, a little is known regarding their cytotoxic effects on health. The purpose of this study was to determine the toxic dose of MgO NPs that prepared by the sol-gel method and the roles of vitamins E and C in the toxicity that is produced by MgO NPs. The MgO NPs were characterized and several amounts (62.5, 125, 250, and 500 mg/kg BW) were orally administered for 28 days to male Wister rats. Toxic dosimetry was evaluated using metal content analysis, hematological, biochemical, histopathological, and serum ROS estimation. Then toxic doses of MgO NPs were administered orally with vitamins E and C, or a combination of them for six weeks, twice a week. The result showed 500 mg/kg bw/day MgO NPs is considered as a toxic and leads to a significant Mg bioaccumulation in the liver ($P < 0.001$) and significantly increased serum ROS ($P < 0.001$) and histopathological damage in the liver and kidney with an immunologic response. Administration of vitamin E with MgO NPs significantly increased serum ROS and adversely affected blood parameters and histological damage to the liver and kidney. The combination of vitamins E and C with MgO NPs significantly reduced the immunologic response to MgO NPs, but serum ROS levels increased significantly with histopathological damage in vital organs. Vitamin C significantly reduced MgO NPs-induced damage in kidney and liver tissues. In the conclusion, MgO NPs are toxic at high doses. Administration of vitamin E alone or combined vitamin E and C with toxic doses of MgO NPs increases their toxicity. However, vitamin C was shown to be histopathologically protective. Therefore, a serious caution should be considered when vitamins are administered with nanoparticles.

KEYWORDS

Hematology, ROS, Bioaccumulation, Metal Content Analysis, MgO Nanoparticle.

1. INTRODUCTION

Magnesium oxide nanoparticles (MgO NPs) are an intriguing basic oxide that is appropriate for the use in a diversity of industries [1]. In the biomedical field, MgO NPs are used as a treatment for heartburn, stomach problems, and bone renewal [2], as an antibacterial agent [3] and as a growth suppressor of tumor cells in cancer [4, 5]. Despite MgO NPs' widespread use, there is a lack of information about their impact on health. The increased

use of these NPs is directly related to levels of human exposure [5]. Experimentally, significant amounts of magnesium have been shown to accumulate in organs and mostly in the liver and kidney. Biochemistry and genotoxicity properties of MgO NPs are changed by dosimetry [6-8]. Reactive oxygen species (ROS) generation by cells indicates oxidative stress and nanotoxicity, which lead to DNA distraction and even

cell degeneration[9, 10]. Vitamins C and E are examples of dietary antioxidants, and they avert oxidative damage, which is a contributor to the pathophysiology and histopathology of many diseases[11-13]. Ascorbic acid (Vitamin C) is soluble in water and overcomes oxidative stress by breaking ROS and reactive nitrogen species (RNS) in biological media[14]. Alpha-Tocopherol (Vitamin E) is soluble in lipid and has a role in preventing lipid peroxidation at the cellular membrane[15]. The role of vitamin C and vitamin E in reducing nanoparticle-induced toxicity has been studied, for instance; nickel nanoparticle-induced reproductive toxicity was significantly reduced by vitamin C[16]. Silver nanoparticles caused a significant toxicity in the salivary glands of albino rats. These toxic effects, however; can be effectively reversed by administration them with vitamin C[17]. Another study showed that vitamin C is a hepatoprotective agent against ZnO-NP toxicity[18]. Even though vitamin C's antioxidant properties are well known, a recent studies illustrated that when present in high intracellular concentrations, it can also cause oxidative stress, which can cause cell degeneration[19, 20]. Some studies have examined the antioxidant capabilities of vitamin E against the toxicity of certain nanoparticles. For example, silver nanoparticles, copper nanoparticles, and titanium dioxide nanoparticles showed reduced toxicity [21-23]. However, new experimental studies on vitamin E safety evaluation have indicated that there are harmful effects on rats when exposed to various amounts of vitamin E [24]. The objective of the current study is to determine MgO NPs toxicity by measuring the bioaccumulation of Mg ions in rats' liver and kidney tissues. in addition to measuring serum oxidative stress, hematological, biochemical, and histological changes that induced by MgO nanoparticles. However, the second part of the study is proposed to determine the role of vitamin C and vitamin E individually, or a combination of these two vitamins in the reduction of the toxic effect of MgO NPs on the biological system.

2. METHODS AND MATERIALS

2.1 Nanoparticle preparation and characterization

The sol-gel auto-combustion method was employed to synthesize magnesium oxide nanoparticles. Stoichiometric amounts of magnesium nitrate Mg (NO₃)₂·6H₂O and citric acid C₆H₈O₇ were weighed and dissolved in deionized water. After combining the containers, pH is adjusted to neutral by adding an ammonia solution drop-by-drop [25]. By gradually increasing the hot plate temperature to 90 °C while stirring continuously, the solutions were transformed into a viscous gel. When the gel was made, the temperature increased, and at about 250 °C, a lot of gases were released, gel self-combustion occurred, and the gel transformed into as-burnt MgO powder. As-burned ashes were thermally calcined at 400, 500, and 600 °C for 3 hours to eliminate organic waste and promote consistency. After that, they were employed for further structural and morphological property

analyses using X-Ray Diffraction (XRD), Field emission-scanning electron microscopy (FE-SEM) and EDS.

2.2 Animal study

In this study, male albino rats of 10-12 weeks of age were used to conduct the study. The rats were allowed to calanite in standard polypropylene cages at an ambient temperature of 22 ± 3 °C with 12 hours of light and 12 hours of dark. The body weight (BW) of the rats at the start of the experiments was 160-200 g. The rats are nourished on a standard diet and given access to pure water freely. Both experiments on the Wister rat were conducted according to the standards of the international animal ethics committee.

2.3 Nanoparticle suspension preparation

MgO nanoparticles were mixed with deionized water and dispersed by ultra-sonication (Qsonica Q700, USA, 30kHz), sonicator for 5 minutes to prepare different concentrations at 62.5, 125, 250, and 500 mg/kg. The concentrations were calculated based on the mean body weight of rats, and the volume of each depended upon body weight.

2.4 Experimental design

2.4.1 Toxicity study of MgO NPs experiment

In this experiment, 25 male albino Wister rats were divided into one control group and four trial groups, each with five animals. The doses of MgO nanoparticles gradually increased (62.5, 125, 250, and 500 mg/kg of BW/day). The MgO NPs were dispersed by sonicator before treatment. The route of administration was performed orally by gavage for 28 days (every day). The control group rats were administrated with deionized water. Food intake and body weight were observed during the experimental period, along with mortality and any signs and symptoms of illness. After 28 days of administration, the rats of all groups were starved overnight and sacrificed after anesthesia by chloroform. The blood samples and organs were collected.

2.4.2 Vitamins supplementation experiment

To determine the effects of vitamin C, vitamin E, and the mix of these two vitamins on the toxicity of MgO NPs, 30 male Wister rats were randomly divided into six groups. Three groups received toxic doses of MgO NPs (500 mg/kg bw) orally by gavage for 28 days (every day) with different vitamins (MgO NPs + 200 mg/kg Vitamin C, MgO NPs + 200 mg/kg Vitamin E, and MgO NPs + Vitamin C & E). Vitamins orally administrated by gavage during the experiment for 6 weeks, twice a week. The control groups were treated twice a week for six weeks orally by gavage with 200 mg/kg vitamin C in distilled water, 200 mg/kg vitamin E in oil, and a combination of the two vitamins. At the end of the experiment, the rats starved overnight and were sacrificed after anesthesia with chloroform. Blood samples are collected and organs are preserved for histopathology examination. The results of groups that received nanoparticles with

vitamins were compared with group that received only 500 mg/kg/day MgO NPs at the first experiment.

2.5 Magnesium content analysis in tissue

A magnesium content analysis of liver and kidney tissues was conducted by a plasma atomic emission spectrometer (ICPE-9820). Tissue samples were collected and weighted by balance, then frozen until the wet digestion procedure started. Starting with weighting 0.3 g of tissue and placing it in a glass digestion tube for predigesting by 1.0 ml of nitric acid (68%-70%) for 12 hours, the samples were heated for 10 h at 80 °C, then heated for 30 min at 130-150 °C. In the final step, 500 µl of perchloric acid (70%) was mixed with the samples and heated for 4 hours until evaporation and nearly dryness. Digested samples are filtered and diluted using 2% nitric acid to a final volume of 25 ml to be used to detect Mg content by ICPE-9820 (Shimadzu Corporation, Japan)[6, 26].

2.6 Hematological test

A complete blood count (CBC) test was performed using an automated hematology analyzer (Swelab Alfa, SE-163 53 Spanga, Sweden) after blood samples was collected via the heart puncture technique and added to an EDTA-K3 tube and gently mixed[7].

2.7 Biochemical tests

Serum is stored at -20 °C until usage. Serum is used for biochemical tests using an automated chemistry analyzer (HITACHI, Roche COBAS C 311, Germany, and Japan).

2.8 Reactive Oxygen Species (ROS) Determination

Serum ROS was determined by an enzyme-linked immunosorbent assay (ELISA) (karyot), BT LAB(KOREA) brand ELISA kit assay.

2.9 Histopathology

Histopathological tests were done to determine any changes in liver and kidney tissue morphology and anatomy. After collection, the tissue was cleaned with 1% cold saline and then preserved with 10% formalin. The samples are processed and fixed in paraffin blocks and cut into 3µm slices by microtome. The fixed slices were stained with hematoxylin and eosin (H&E) stain and immobilized on glass slides. The examination was done using a binocular microscope, and light micrographs of the fixed organs were obtained.

2.10 Statistical analysis

Statistical analyses were performed with GraphPad Prism version 8.2 (GraphPad, California, USA). The experimental results were expressed as a mean ± standard deviation. Groups were compared by analysis of variance using ANOVA followed by Tukey's post hoc test, and different letters refer to significant differences between the means.

3. RESULTS

3.1 MgO NPs characterization

3.1.1 XRD studies

Utilizing X-Ray Diffraction (XRD) model PANalytical (Xpert Pro, Netherlands) equipped with a Cu k radiation source ($\lambda = 1.5406 \text{ \AA}$) at room temperature, the powder crystalline size and its identification were investigated. The sharpness of the XRD patterns illustrated in (Figure 1) revealed the characteristics of MgO NPs samples calcined for 3 hours at 400, 500, and 600 °C. The patterns exhibit cubic magnesium oxide with a single fcc phase structure, and the well-defined pure phase of MgO NPs is indicated by the index of crystal planes (111, 200, 220, 311, and 222) for all patterns. Using the Scherrer formula and XRD data[27], the average crystallite size was (7.05, 8.9, and 11.77) for the temperatures of 400, 500, and 600 °C, respectively.

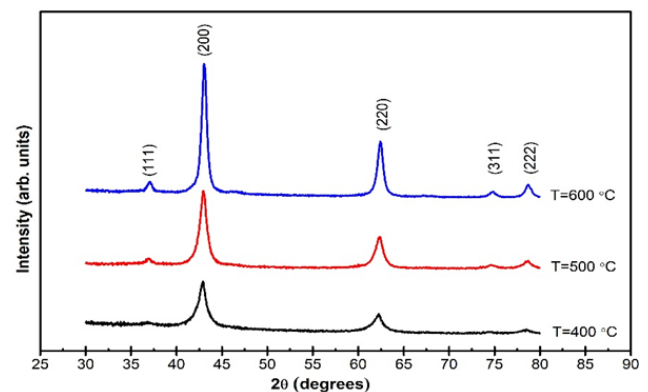
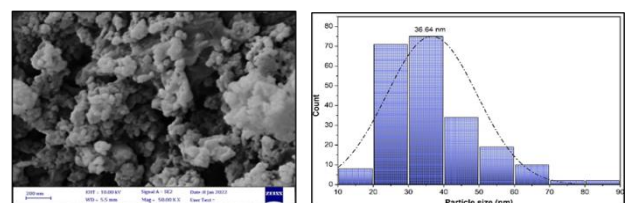


Figure 1: XRD patterns of MgO NPs samples calcined at 400, 500, and 600 °C.

3.1.2 Morphology and purity studies

A field emission-scanning electron microscopy model (Mira3-XMU, TESCAN, Japan) was utilized to investigate the surface morphology and EDS spectra. As indicated in (Figures 2. A-C), the surface morphology and histogram distribution of MgO NPs samples calcined at various temperatures were examined at room temperature. The particles sized by the FE-SEM image are expected to be composed of a large number of nano-crystals as identified by XRD. At temperatures of 400, 500, and 600 °C, the average particle size was (36.64, 41.27, and 51.87). Energy dispersive spectroscopy (EDS) indicates that all unwanted precursors, such as nitrate ions, are removed, leaving Mg and O as the main components of the product.



A

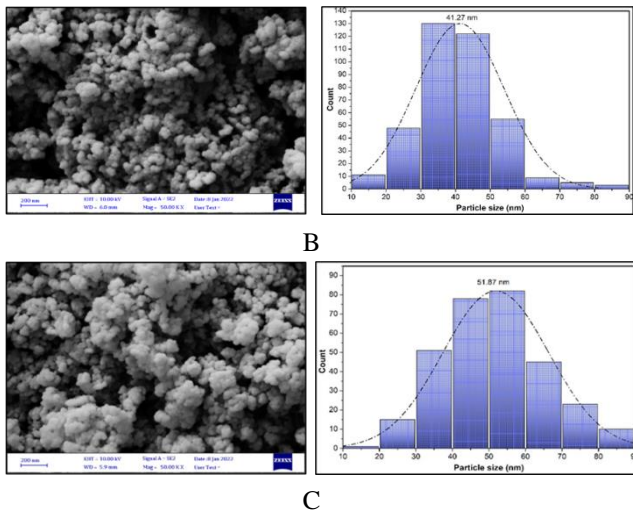


Figure 2: FESEM images and frequency distribution histogram of MgO nanoparticles calcined (A) at 400 °C, (B) at 500 °C, and (C) at 600 °C.

3.2 Magnesium content analysis

The analysis of Mg content after 28 days of oral administration with MgO NPs at several doses (62.5, 125, 250, and 500 mg/kg BW) in male Wistar rats was performed for liver and kidney tissues. Tissues were digested for Mg content analysis by ICPE-9820. The results showed that Mg accumulation was significant in the livers of rats that administered with MgO NPs at 500 mg/kg ($P < 0.001$), but not in the livers of rats administered with other doses of MgO NPs (62.5, 125, and 250 mg/kg), as shown in (Figure 3. A). Mg accumulation in kidney tissue did not differ significantly between the control and all dose groups (Figure 3. B).

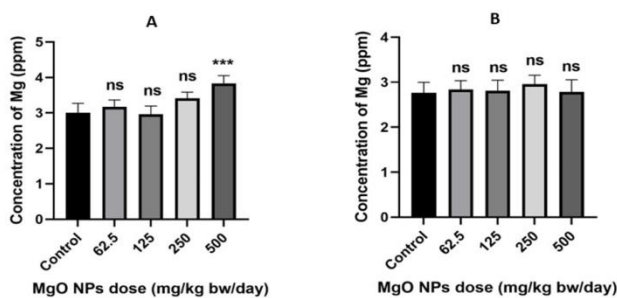


Figure 3: Magnesium content of tissues analyzed by ICPE-9820 in rats after 28 days of oral treatment with 62.5, 125, 250, and 500 mg/kg BW/day of MgO NPs in (A) liver and (B) kidney. Significantly different from control (deionized water) at * = $P < 0.05$, ** = $P < 0.01$ and *** = $P < 0.001$, $n = 5$ animals per group.

3.3 Hematological investigations

3.3.1 Experiment 1/toxicity of MgO NPs

The CBC results illustrated that the WBC, LYM, HGB, HCT, and MCV values of the MgO NPs treated rats after 28 days of oral administration were increased significantly in a dose-dependent manner compared to the control group ($P \leq 0.05$). However, in all doses of MgO NPs, the RBC and PLT levels of the treated rats were not changed significantly (Table 1).

Table 1: Hematological test of Wister rats after 28 days of administration with different doses of MgO NPs.

Hematological parameters	MgO NPs Doses (mg/kg bw/day)				
	Control	62.5	125	250	500
WBC (103/ μ L)	6.850 \pm 0.99	14.63 \pm 0.91d	13.95 \pm 1.49d	13.60 \pm 0.65d	16.38 \pm 0.79d
LYM (103/ μ L)	5.200 \pm 0.86	12.25 \pm 0.79d	12.08 \pm 0.41d	11.25 \pm 0.75d	13.76 \pm 0.88d
RBC (106/ μ L)	7.523 \pm 0.36	7.395 \pm 0.28	7.425 \pm 0.26	7.363 \pm 0.23	7.493 \pm 0.45
HGB (g/dL)	14.15 \pm 0.38	15.60 \pm 0.24b	15.33 \pm 0.55a	15.50 \pm 0.53b	15.70 \pm 0.58b
HCT %	39.33 \pm 0.63	44.73 \pm 0.96c	43.70 \pm 1.92b	43.15 \pm 1.41b	44.13 \pm 0.80c
MCV (fL)	52.30 \pm 1.73	60.50 \pm 1.58d	58.83 \pm 0.63c	58.58 \pm 0.73c	57.88 \pm 2.40c
PLT (103/ μ L)	668.8 \pm 2.692	753.5 \pm 41.88	765.0 \pm 43.64	705.5 \pm 55.26	773.5 \pm 65.47

Statistics showed a mean \pm S.D, significantly different from control (deionized water) at ^a $P < 0.05$, ^b $P < 0.01$, ^c $P < 0.001$ and ^d $P < 0.0001$, $n = 5$ animals per group.

3.3.2 Experiment 2/vitamin supplementation

Hematological parameters were significantly changed between the control group treated only with 500 MgO NPs mg/kg BW/days for 28 days and the other groups, which were administered with (500 MgO NPs mg/kg) for 28 days with different vitamins twice a week for 6 weeks. In the vitamin E + MgO NPs treated group, HCT was significantly decreased compared to the control group ($P < 0.05$), while WBC, LYM, RBC, HGB, MCV, and PLT were not changed significantly. In the mixed vitamins+MgO NPs group, WBC, LYM, and HCT were decreased significantly compared to the control group ($P < 0.05$), while RBC, HGB, MCV, and PLT levels were not changed significantly. In the Vitamin C + MgO NPs treated group, levels of HCT and MCV were decreased significantly compared to the control group, $P < 0.05$, while levels of WBC, LYM, RBC, HGB, and PLT were not significantly changed (Table 2).

Table 2: Hematological test of Wister rats after 28 days of administration of 500 mg/kg BW/day MgO NPs with different vitamins.

Hematological parameters	MgO NPs 500 (mg/kg bw/day) with different vitamins.			
	Control (NPs)	NPs and VE	NPs and V Mix	NPs and VC
WBC (103/ μ L)	16.38 \pm 0.79	15.36 \pm 0.90	11.05 \pm 0.30d	15.20 \pm 0.68
LYM (103/ μ L)	13.76 \pm 0.88	13.64 \pm 0.58	9.775 \pm 58d	13.74 \pm 0.56
RBC (106/ μ L)	7.493 \pm 0.45	7.370 \pm 0.21	7.350 \pm 0.41	7.254 \pm 0.31
HGB (g/dL)	15.70 \pm	15.44	15.45 \pm	14.80 \pm

	0.58	± 0.63	0.66	0.39
HCT %	44.13 ± 0.80	40.98 ± 1.57a	41.33 ± 1.31a	39.18 ± 1.30c
MCV (fL)	57.88 ± 2.40	55.60 ± 1.47	56.30 ± 1.65	54.00 ± 0.84a
PLT (103/μL)	773.5 ± 5.47	823.6 ± 61.36	729.3 ± 20.07	814.6 ± 48.50

Statistics showed a mean ± S.D, significantly different from control (MgO NPs 500 mg/kg bw) at ^aP<0.05, ^bP<0.01, ^cP<0.001 and ^dP<0.0001, n= 5 animals per group.

3.4 Biochemical Analysis

3.4.1 Experiment 1/ toxicity of MgO NPs

The serum biochemical tests analyzed in the male Wistar rats, which received several doses (62.5, 125, 250, and 500 mg/kg BW) for 28 days of sol-gel prepared MgO NPs. The results illustrated that there were no significant differences in all biochemical parameters that performed between the control group and treated groups (Table 3).

Table 3: Biochemical tests of Wister rats after 28 days of taking different doses of MgO NPs

Biochemical parameters	MgO NPs Doses (mg/kg bw/day)				
	Control	62.5	125	250	500
ALB (g/dl)	4.28 ± 0.28	4.32 ± 0.19	4.29 ± 0.18	4.31 ± 0.11	4.24 ± 0.21
ALP (U/L)	218.2 ± 10.87	226.6 ± 8.23	228.3 ± 6.34	230.3 ± 4.11	228.8 ± 8.34
ALT (U/L)	34.48 ± 2.17	36.68 ± 1.95	34.03 ± 2.03	36.31 ± 2.41	37.29 ± 2.24
AST (U/L)	92.85 ± 7.72	89.05 ± 8.67	96.18 ± 4.86	91.78 ± 6.82	89.02 ± 4.22
LDH (U/L)	392.4 ± 20.72	419.8 ± 26.22	420.8 ± 25.02	425.0 ± 44.73	438.0 ± 22.95
TP (g/dl)	5.86 ± 0.55	6.48 ± 0.45	6.27 ± 0.36	6.21 ± 0.11	6.51 ± 0.31
Bili T (mg/dl)	0.098 ± 0.006	0.093 ± 0.006	0.100 ± 0.004	0.100 ± 0.007	0.096 ± 0.009
Mg (mg/dl)	2.50 ± 0.13	2.54 ± 0.16	2.55 ± 0.17	2.41 ± 0.18	2.58 ± 0.20
BUN (mg/dl)	19.60 ± 1.81	21.00 ± 1.63	22.25 ± 1.25	21.00 ± 1.82	19.80 ± 1.48
CREA (mg/dl)	0.29 ± 0.02	0.28 ± 0.02	0.29 ± 0.02	0.29 ± 0.01	0.29 ± 0.01
UA (mg/dl)	1.00 ± 0.14	1.10 ± 0.18	1.00 ± 0.08	0.80 ± 0.14	0.76 ± 0.19
UREA (mg/dl)	38.42 ± 2.76	44.63 ± 3.72	42.35 ± 3.93	40.13 ± 3.15	39.62 ± 2.88
CHOLI (mg/dl)	84.42 ± 3.49	78.55 ± 3.33	76.85 ± 4.24	80.03 ± 6.41	78.57 ± 3.07

TG (mg/dl)	99.53 ± 8.83	108.20 ± 9.99	112.10 ± 8.51	102.8 ± 13.24	91.11 ± 10.64
HDL (mg/dl)	58.63 ± 6.92	53.63 ± 5.63	54.33 ± 7.35	54.18 ± 8.09	51.62 ± 7.99
LDL (mg/dl)	20.88 ± 2.12	20.55 ± 2.59	19.91 ± 1.94	23.33 ± 2.19	20.54 ± 2.06

Statistics displayed a mean ± S.D, significantly different from control (deionized water) at ^aP<0.05, ^bP<0.01, ^cP<0.001 and ^dP<0.0001, n= 5 animals/group.

3.4.2 Experiment 2/vitamin supplementation

The effects of several vitamins (vitamin C, vitamin E, and a mix of vitamin C and E) on serum biochemistry after oral administration twice a week for six weeks on rats treated with MgO NPs 500 mg/kg for 28 days were analyzed. The results were compared with the control group treated only with MgO NPs 500 mg/kg for 28 days. The result illustrated that AST, LDH, CREA, and TG serum levels were significantly increased in the vitamin E+ MgO NPs treated group compared to the control group (MgO NPs only). However, bilirubin total and HDL levels were decreased (P<0.05). Other parameters, such as ALB, ALP, ALT, TP, Mg, BUN, UA, UREA, CHOLI, and LDL, were not changed significantly. In the case of vitamin C+ MgO NP treated group, the level of LDH was increased significantly in comparison to the control group, while the levels of ALB, TP, ALT, Bili T, and HDL were decreased significantly. Other parameters did not change significantly. The mixed vitamin E and C + MgO NPs treated group displayed that the levels of LDH, CREA, and LDL were significantly increased compared to the control group, but the level of Bili T was decreased (P<0.05). The remaining parameters were not changed significantly (Table4).

Table 4: The biochemical test of Wister rats after 28 days of administration of a 500 mg/kg bw/day dose of MgO NPs with different vitamins

Biochemical parameters	MgO NPs 500 (mg/kg bw/day) with different vitamins.			
	Control (NPs)	NPs + VE	NPs + VMIX	NPs + VC
ALB (g/dl)	4.24 ± 0.21	4.16 ± 0.27	4.05 ± 0.04	3.19 ± 0.13d
ALP (U/L)	228.8 ± 8.34	207.8 ± 20.27	256.3 ± 21.53	251.2 ± 26.96
ALT (U/L)	37.29 ± 2.24	36.86 ± 3.91	34.01 ± 2.49	27.01 ± 2.59 c
AST (U/L)	89.02 ± 4.22	123.5 ± 7.60d	91.85 ± 8.57	87.42 ± 11.48
LDH (U/L)	438.0 ± 22.95	771.8 ± 41.12d	758.5 ± 48.13d	751.8 ± 55.50d
TP (g/dl)	6.51 ± 0.31	6.60 ± 0.45	6.25 ± 0.07	5.30 ± 0.34c
Bili T (mg/dl)	0.096 ± 0.009	0.076 ± 0.01a	0.077 ± 0.006a	0.077 ± 0.01a
Mg (mg/dl)	2.58 ±	2.81 ±	2.93 ±	2.29 ±

	0.20	0.30	0.17	0.14
BUN (mg/dl)	19.80 ± 1.48	17.80 ± 0.83	18.00 ± 1.41	19.20 ± 1.92
CREA (mg/dl)	0.29 ± 0.01	0.41 ± 0.01c	0.44 ± 0.02d	0.31 ± 0.04
UA (mg/dl)	0.76 ± 0.19	0.72 ± 0.16	0.90 ± 0.16	0.52 ± 0.38
UREA (mg/dl)	39.62 ± 2.88	37.84 ± 1.70	35.38 ± 2.13	39.12 ± 2.40
CHOLI (mg/dl)	78.57 ± 3.07	83.12 ± 5.26	86.58 ± 5.02	76.71 ± 5.53
TG (mg/dl)	91.11 ± 10.64	123.0 ± 8.37c	102.9 ± 12.89	107.3 ± 6.04
HDL (mg/dl)	51.62 ± 7.99	39.68 ± 4.77a	44.98 ± 4.80	35.48 ± 4.95b
LDL (mg/dl)	20.54 ± 2.06	21.78 ± 2.10	25.20 ± 2.39a	17.20 ± 2.35

Statistics displayed a mean ± S.D, significantly different from control (MgO NPs 500 mg/kg) at ^aP<0.05, ^bP<0.01, ^cP<0.001 and ^dP<0.0001, n= 5 animals/group.

3.5 Reactive Oxygen Species (ROS) detection

3.5.1 Experiment 1/ toxicity of MgO NPs

Serum ROS levels were analyzed in the Wistar rats, which received several doses (62.5, 125, 250, and 500 mg/kg bw) of MgO NPs after 28 days of oral administration and compared to the control group. The outcomes demonstrated that ROS levels were increased significantly in all administrated groups with nanoparticles in comparison to the control group at P<0.05 (Figure4).

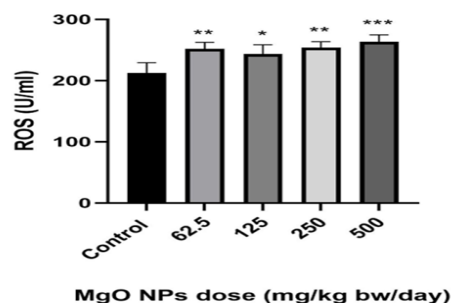


Figure 4: Serum ROS level measured by ELISA, in Wistar rats after 28 days of oral administration of 62.5, 125, 250, 500

mg/kg bw/day of MgO NPs. Significantly different from control (deionized water) at * = P<0 .05, ** = P< 0.01 and *** = P< 0.001, n = 5 animals per group.

3.5.2 Experiment 2/vitamin supplementation

The serum ROS levels after oral treatment with MgO NPs 500 mg/kg b for 28 days with several vitamins (vitamin C, vitamin E, and a mix of vitamins C and E) twice weekly for six weeks were analyzed . The results were compared to the control group, which received only 28 days of MgO NPs treatment at 500 mg/kg bw. The result illustrated that the serum ROS level was increased significantly after the administration of vitamin E and vitamin E+C with MgO NPs in comparison to the control group (MgO NPs)

(P<0.001). However, the level of ROS in the vitamin C + MgO NPs treated group was not changed significantly compared to the control group (Figure5).

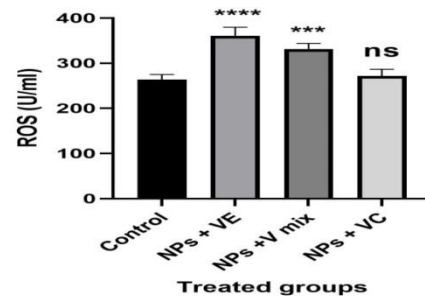


Figure 5: Serum ROS levels were measured by ELISA in Wister rats treated with several vitamins and MgO NPs. Significantly different from control(MgO NPs) at * = P<0 .05, ** = P< 0.01, *** = P< 0.001 and **** = P< 0.0001. n = 5 animals per group

3.6 Histopathology analysis

3.6.1 Experiment 1/ toxicity of MgO NPs

A histological investigation of the liver and kidney tissues was performed for investigation the toxicity of MgO nanoparticles; the results are shown in (Figure 6). The rats treated with MgO nanoparticles showed some modification in the liver and kidney architecture at high dose concentrations of 500 mg/kg, while the liver and kidney of the control group displayed normal architecture.

3.6.2 Experiment 2/vitamin supplementation

Figure 7 displays the findings from a histopathological study of the liver and kidney tissues to determine the roles of several vitamins (vitamin E, vitamin C, and a combination of vitamin E and C) on the toxicity of MgO nanoparticles.

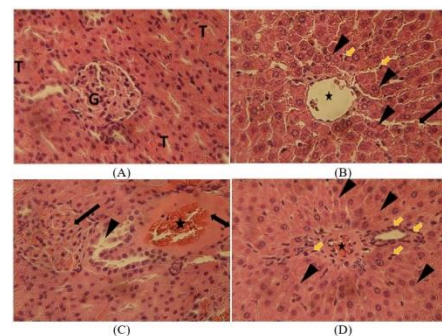


Figure 6: (A) The control rat kidney micrograph shows normal histological architecture, glomeruli (G), and tubules (T). (B)The liver of the control rat group represents normal histological architecture, with central vein (*), hepatocytes (arrowhead), kuffer cells (yellow arrow), and sinusoids (arrow). (C) The kidney of a rat administrated with 500 mg/kg of MgO nanoparticles for (28 days) demonstrating glomerular congestion (arrow), vascular dilatation and congestion (*), eosinophilic exudative material (bi headed arrow), and hydropic degeneration of tubular epithelial lining (arrow head).(D)The liver of a rat exposed to 500 mg/kg of MgO nanoparticles for 28 days, revealing central vein hyperemia with eosinophilic exudative material (*), infiltration of inflammatory cells (yellow arrow), and swelling of hepatocytes (arrow head). H & E stain, 400.

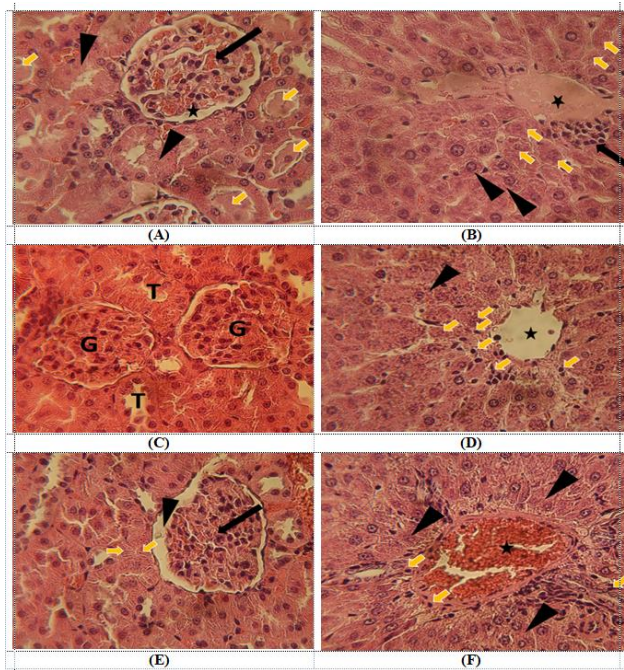


Figure 7: (A) The kidney photomicrograph of a rat exposed to 500 mg/kg MgO NPs for (28 days) and vitamin E (200 mg/kg) for (6 weeks) demonstrates glomerular hemorrhage (arrow) with increased Bowman's capsular space (*), degeneration and necrosis of renal tubular epithelial cells (arrow head), and the intraluminal hyaline cast is seen within the tubular space (yellow arrow head). (B) The liver of a rat exposed to 500 mg/kg MgO NPs for (28 days) and vitamin E (200 mg/kg) demonstrating a central vein filled with eosinophilic material (*), with necrotic hepatocytes around it some with Karyorrhexis (yellow arrow head), and hepatocytes showing swelling (arrow head), and activated inflammatory cells also seen (arrow). (C) The kidney of rat exposed to 500 mg/kg MgO NPs and vitamin C (200 mg/kg) for (6 weeks) demonstrating that treatment reduced the occurrence of histopathological changes and reversed the nanoparticle induced lesions, T = tubules, G = glomerulus. (D) The liver of a rat exposed to 500 mg/kg MgO NPs and vitamin C (200 mg/kg) demonstrates a central vein without lesion (*), with necrotic hepatocytes around it, some with pyknosis (yellow arrow head), and hepatocytes showing swelling (arrow head). (E) The kidney of a rat exposed to 500 mg/kg MgO NPs and mixed vitamins for 6 weeks demonstrates glomerular congestion and shrinkage (arrow) with increased Bowman's capsular space (arrow head), vascular dilatation and congestion (*), and degeneration of renal tubular epithelial cells with pyknotic nuclei (yellow arrow head). (F) The liver of a rat exposed to 500 mg/kg MgO NPs and mixed vitamins, revealing central vein hyperemia (*), infiltration of inflammatory cells (yellow arrow), and swelling of hepatocytes (arrow head). H & E stain, 400.

4. DISCUSSION

MgO NPs are metal oxide nanoparticles that have been used in a variety of biomedical applications. Despite the extensive use of MgO NPs, information about their cytotoxic impact on health is limited[5]. Hence, the present study aimed to determine the best way to prepare MgO NPs by the sol-gel method and to select the toxic dose of MgO NPs in male Wister rats after oral administration for 28 days. Following that, several vitamins have been used to determine their antioxidant roles in reducing MgO NPs toxicity. The properties of MgO NPs prepared by the sol-gel method and calcined at various temperatures

are determined by suitable analytical methods. The XRD analysis showed that the intensity of the XRD peaks indicated the distinctive patterns and suggested the formation of crystalline MgO NPs samples at 400, 500, and 600 °C for 3 hours. As the calcination temperature increased, it was observed that the peaks became higher and sharper due to agglomeration, and crystallite size increased[28]. The FE-SEM image showed that the diameter of MgO nanoparticles is significantly larger than the size of crystallites as revealed by XRD. Increasing calcination temperature influences the MgO nanoparticles' porosity structure, high spherical particle aggregation, and increase in particle size[29] because of the fusing of adjacent small particles by melting their surfaces, and the elevated surface energy of the MgO nanoparticle [30]. The EDS spectrum indicated an acceptable purity of MgO. The size of the particle is the most important factor in its toxicity. The small size of nanoparticles allows them to easily enter the cells, and this makes them more toxic[31]. MgO NPs prepared by the sol-gel method and calcinated at 500 °C were used to investigate this study.

Bioaccumulation of nanoparticles helps to predict and understand the probable mechanism of toxicity[6]. The bioaccumulation of Mg ions in the liver and kidney tissues of rat groups exposed to different doses of MgO NPs for 28 days was dose-dependent. The liver of the rat group exposed to 500 mg/kg MgO NPs showed a significant accumulation of Mg in liver tissues, while the accumulation of Mg in the liver of other groups was not significant in comparison with the control group. However, the bioaccumulation of Mg in the kidney was not significant in all groups by the sol-gel prepared MgO nanoparticles and that could be due to a difference in nanoparticle size and properties. Mg ions released from MgO nanoparticles pass through the digestive system and accumulate in the liver, which is the main site of metabolism[7]. The kidney is an excretory organ, so that is the second organ after the liver that gets bioaccumulation[6].

The hematological results showed that (WBC), (LYM), (Hb), (HCT), and (MCV) were elevated significantly in rats administered by MgO NPs in a dose-dependent comparison to the control group. (RBC) and (PLT) were not changed significantly. Increases in (WBC) and (LYM) are inflammatory responses[8, 32], that activate the innate immune system[6, 7]. However, increased (Hb), (HCT), and (MCV) could indicate a greater need for oxygen, disrupting normal cell physiology [33, 34] or could be a hematopoietic system affected[8, 32]. Nanoparticles themselves or the components that make up the particles can cause toxicity once they exit the bloodstream and enter the liver and kidneys. Liver function tests indicate hepatic damage and cholestasis[32, 35, 36]. Kidney function tests indicate kidney function and injury[32]. The serum biochemistry of rats exposed to MgO nanoparticles in the study is normal in the dependent doses compared to the control group

(Table 4). Despite significant bioaccumulation of Mg ions in the liver of rats administrated with 500 mg/kg MgO NPs, the levels of ALT, AST, and ALP did not change significantly. However, similar results were found by another study in the serum and tissue homogenate of rats treated with 500 mg/kg MgO NPs, but there was an elevation of levels of AST and ALT in the serum and tissue homogenate after oral administration with 1000 mg/kg MgO NPs because of the dose-dependent toxicity[6, 7]. Administration of MgO nanoparticles for 28 days caused significant production of ROS, especially at high doses. Nanoparticle induced ROS may cause significant damage in cells, which leads to oxidation of proteins and an unbalancing of redox potential in the cell environment[37]. ROS disrupts membrane lipids by lipoperoxidation[38] and attaches DNA and causes genotoxicity induced by nanoparticles[39]. Mangalampalli et al. reported altered antioxidant status in tissue homogenates by oral administration of high dose MgO NPs[7]. Histopathological examination of kidney tissues following administration of 500 mg/kg MgO NPs showed remarkable morphological alterations like glomerular congestion, vascular dilatation and congestion, eosinophilic exudative material, and hydropic degeneration of the tubular epithelial lining in kidney tissues. However, a light micrograph of the rat liver reveals central vein hyperemia with eosinophilic exudative material, inflammatory cell infiltration, and hepatocyte swelling. Other studies on the MgO nanoparticles revealed similar hepatic and renal changes[6, 7]. Following the first experiment to determine the toxic dose of MgO NPs, several vitamins have been used to determine their antioxidant roles to reduce MgO NPs toxicity. When nanoparticles are used in complicated systems, their toxicity may have changed significantly. Several factors influence how nanoparticles are endocytic. Like the composition, size, shape, and surface characteristics of nanoparticles[40]. The administration of supplements with nanoparticles may alter the endocytosis rate of the nanoparticle by altering its size, zeta potential, and dissociation rate. The endocytosis rate is the primary contributor to nanoparticle toxicity[20]. Combined treatment of MgO NPs 500 mg/kg for 28 days with Vitamin E (200 mg/kg) twice a week for six weeks showed that vitamin E decreased HCT without any significant change in blood cell count or size (WBC, LYM, RBC, HGB, MCV, and PLT). This decrease in HCT may be due to increasing plasma volume by disruption in plasma volume balance caused by vitamin E or blood loss. A similar result was obtained by another study when vitamin E was used to reduce the toxicity of the highest concentration of paraquat[41]. This indicates that vitamin E does not have an effect on the total WBC count and lymphocytes. Serum biochemistry tests illustrated that AST, LDH, and CREA serum levels were significantly increased in the group treated with

vitamin E and MgO NPs. However, bilirubin total was decreased, and TG increased while HDL decreased. Increase AST and ALT levels are indicators of hepatic disorders[36]. However, the activity of lactate dehydrogenase (LDH) is not specific when vital organs such as the heart, muscle, kidney, liver, etc are injured, LDH is moved into the circulation because of changes in the permeability of the plasma membrane by free radicals[42]. Raising serum creatinine levels could indicate a kidney problem. Because the kidney is considered the second route of excretion of vitamin E [43]. Total proteins, uric acid, and bilirubin are the serum components that act as free radical scavengers. According to recent research, bilirubin is a powerful biological antioxidant[44, 45]. The decrease of total bilirubin after vitamin E administration may be as a result of increasing serum free radicals or may be due to hepatic injury. Vitamin E is known as a lipid-soluble antioxidant. Following oral ingestion, the route of vitamin E generally follows that of other lipids[15], so a change occurred in the levels of serum triglyceride and HDL after vitamin E oral administration. Administration of vitamin E with MgO NPs increased serum ROS significantly. Similar results were obtained by J. Abilés et al. (2006) when oxidative stress is elevated in critically ill patients by antioxidant vitamin treatment because of changes in internal levels of components with antioxidant capacity related to redox imbalance[44]. Histopathological administration of vitamin E with MgO nanoparticles does not show any sign of improvement in kidney and liver tissue damage caused by MgO NPs. The kidney is the main site for the excretion of vitamin E [43]. The kidney histopathology demonstrates glomerular hemorrhage with increased Bowman's capsular space, degeneration and necrosis of renal tubular epithelial cells, and the intraluminal hyaline cast is seen within the tubular space. This will be the cause of a decrease in hematocrit and an increase in serum creatine, AST, and LDH levels, which are linked to kidney damage. Another sign of nephron damage is the presence of hyaline casts. The liver histopathology demonstrates a central vein filled with eosinophilic material, with necrotic hepatocytes around it, some with karyorrhexis, and hepatocytes showing swelling. Activated inflammatory cells are also seen. The liver damage is caused by its function as the target stored organ for vitamin E[24], and the primary site of Mg bioaccumulation[6], this may be the cause of serum bilirubin total depletion and elevation of AST and LDH. A similar result was investigated when high dose subcutaneous treatment of vitamin E caused liver injury by ALT and AST elevation, and they illustrated that may be due to hepatic necrosis[24]. Combined treatment of vitamins (E 200 mg/kg and C 200 mg/kg) twice a week for six weeks with 500 mg/kg bw/day MgO NPs for 28 days decreased WBC, LYM, and HCT levels significantly, while RBC, HGB, MCV, and PLT levels were not

changed significantly. Changes in these hematological parameters could be a result of decreased inflammatory response, the hematopoietic system being affected or blood loss. The results are in the agreement with a study showed that a mixture of vitamin C and vitamin E reduced WBC approximately to their normal values after increasing by nickel treatment[46]. Biochemistry tests showed that administration of vitamin E + C with MgO NPs increased serum LDH, creatine, and LDL while decreasing bilirubin total. This may be as a result of hepatic and kidney injury. As well as serum ROS showed a significant increase, despite the antioxidant properties of these two vitamins. Histopathological examination of the kidney demonstrated glomerular congestion and shrinkage with increased Bowman's capsular space, vascular dilatation and congestion, and degeneration of renal tubular epithelial cells with pyknotic nuclei. The liver micrographs revealed central vein hyperemia, infiltration of inflammatory cells, and swelling of hepatocytes. In contrast to the current study, vitamin E, vitamin C, and selenium treatment reduce the toxicity, stop neutrophil infiltration, and preserve the structural integrity of the liver[47].

A combined treatment of MgO NPs with vitamin C was tested to investigate the protective effect of vitamin C on the toxicity induced by MgO NPs. Vitamin C decreased HCT and MCV, which could be attributed to their effect on the hematopoietic system. However, the level of LDH was increased significantly in comparison to the group that received only MgO NPs, while the levels of ALB, TP, ALT, Bili T, and H DL were decreased by vitamin C administration. The liver is the site for the synthesis of these proteins and pigments, so decreased levels may be due to liver problems. However, increased LDH may indicate injury has occurred in vital organs that contain this enzyme. Serum ROS showed no significant change following vitamin C administration and histopathological examination of the kidney, demonstrating that treatment reduced the occurrence of histopathological changes and reversed the nanoparticle-induced lesions. A liver micrograph demonstrates a central vein without lesion, with necrotic hepatocytes around it, some with pyknosis, and hepatocytes showing swelling. The results are in contrast with another study demonstrated that the combination of vitamin C and ZnO NPs causes combined toxicity because vitamin C makes the medium acidic and the ZnO NPs dissolution rate increases, resulting in an increase in Zn²⁺ inside the cells[20]. From the current results, we infer that vitamin C was found to have a histopathological protection against MgO NPs toxicity.

5. CONCLUSION

The in vivo toxicity of MgO NPs produced in animal systems was found to be dose dependent. The

treatment of vitamin E with MgO NPs, as well as the combination of vitamins E and C with MgO NPs, is not safe and has a negative impact on essential organs. Vitamin C, on the other hand, was found to be histopathologically protective against MgO NPs. MgO NPs should be used with low doses in biomedical applications and care should be taken when antioxidants such as vitamin C and vitamin E are used with medications containing MgO NPs. Vitamins are recognized as being essential for human health, but taking them with nanoparticles may lead to undesired health consequences. More research about the effects of vitamins on nanoparticle toxicity is required. The obtained results can provide a reference for the combined toxicity of nanoparticles and vitamins.

REFERENCE

- [1] Z. Camtakan, S. Erenturk, and S. Yusan, "Magnesium oxide nanoparticles: preparation, characterization, and uranium sorption properties," *Environmental Progress & Sustainable Energy*, vol. 31, no. 4, pp. 536-543, 2012.
- [2] L. Bertinetti *et al.*, "Surface characteristics of nanocrystalline apatites: effect of Mg surface enrichment on morphology, surface hydration species, and cationic environments," *Langmuir*, vol. 25, no. 10, pp. 5647-5654, 2009.
- [3] P. Bhattacharya, A. Dey, and S. Neogi, "An insight into the mechanism of antibacterial activity by magnesium oxide nanoparticles," *Journal of Materials Chemistry B*, vol. 9, no. 26, pp. 5329-5339, 2021.
- [4] D.-R. Di, Z.-Z. He, Z.-Q. Sun, and J. Liu, "A new nanocryosurgical modality for tumor treatment using biodegradable MgO nanoparticles," *Nanomedicine: Nanotechnology, Biology and Medicine*, vol. 8, no. 8, pp. 1233-1241, 2012.
- [5] K. Krishnamoorthy, J. Y. Moon, H. B. Hyun, S. K. Cho, and S.-J. Kim, "Mechanistic investigation on the toxicity of MgO nanoparticles toward cancer cells," *Journal of materials chemistry*, vol. 22, no. 47, pp. 24610-24617, 2012.
- [6] B. Mangalampalli, N. Dumala, and P. Grover, "Acute oral toxicity study of magnesium oxide nanoparticles and microparticles in female albino Wistar rats," *Regulatory Toxicology and Pharmacology*, vol. 90, pp. 170-184, 2017.
- [7] B. Mangalampalli, N. Dumala, R. Perumalla Venkata, and P. Grover, "Genotoxicity, biochemical, and biodistribution studies of magnesium oxide nano and microparticles in albino Wistar rats after 28-day repeated oral exposure," *Environmental Toxicology*, vol. 33, no. 4, pp. 396-410, 2018.
- [8] N. Mazaheri, N. Naghsh, A. Karimi, and H. Salavati, "In vivo toxicity investigation of magnesium oxide nanoparticles in rat for environmental and biomedical applications," *Iranian journal of biotechnology*, vol. 17, no. 1, 2019.
- [9] H. C. Fischer and W. C. Chan, "Nanotoxicity: the growing need for in vivo study," *Current opinion in biotechnology*, vol. 18, no. 6, pp. 565-571, 2007.
- [10] M. Hanot-Roy *et al.*, "Oxidative stress pathways involved in cytotoxicity and genotoxicity of titanium dioxide (TiO₂) nanoparticles on cells constitutive of alveolo-capillary barrier in vitro," *Toxicology in vitro*, vol. 33, pp. 125-135, 2016.
- [11] G. Fabre *et al.*, "Synergism of antioxidant action of vitamins E, C and quercetin is related to formation of molecular associations in biomembranes," *Chemical Communications*, vol. 51, no. 36, pp. 7713-7716, 2015.
- [12] B. W. Magdy, F. E. s. Mohamed, A. S. Amin, and S. S. Rana, "Ameliorative effect of antioxidants (vitamins C and E) against abamectin toxicity in liver, kidney and testis of male albino rats," *The Journal of Basic & Applied Zoology*, vol. 77, pp. 69-82, 2016.

- [13] S. B. Nimse and D. Pal, "Free radicals, natural antioxidants, and their reaction mechanisms," *RSC advances*, vol. 5, no. 35, pp. 27986-28006, 2015.
- [14] E. Niki, "Synergistic inhibition of oxidation by vitamin E and vitamin C," in *Cellular Antioxidant Defense Mechanisms*: CRC Press, 2019, pp. 111-122.
- [15] P. Konieczka, M. Barszcz, M. Choct, and S. Smulikowska, "The interactive effect of dietary n-6: n-3 fatty acid ratio and vitamin E level on tissue lipid peroxidation, DNA damage in intestinal epithelial cells, and gut morphology in chickens of different ages," *Poultry Science*, vol. 97, no. 1, pp. 149-158, 2018.
- [16] L. Kong, W. Hu, C. Lu, K. Cheng, and M. Tang, "Mechanisms underlying nickel nanoparticle induced reproductive toxicity and chemo-protective effects of vitamin C in male rats," *Chemosphere*, vol. 218, pp. 259-265, 2019.
- [17] M. Shamel, D. Riad, and M. Al Ankily, "Histological and ultrastructural study of silver nanoparticles toxicity and the possible protective effect of vitamin c on submandibular salivary glands of albino rats," 2021.
- [18] D. Nemenqani, O. El-Gharib, A. M. Ahmed, and A. R. Baiuomy, "The protective effects of antioxidant (vitamin C) against hepatic oxidative damage induced by zinc oxide nanoparticles," *IRJABS*, vol. 9, no. 4, pp. 502-9, 2015.
- [19] A. Chakraborty and N. R. Jana, "Vitamin C-conjugated nanoparticle protects cells from oxidative stress at low doses but induces oxidative stress and cell death at high doses," *ACS applied materials & interfaces*, vol. 9, no. 48, pp. 41807-41817, 2017.
- [20] Y. Wang *et al.*, "A combined toxicity study of zinc oxide nanoparticles and vitamin C in food additives," *Nanoscale*, vol. 6, no. 24, pp. 15333-15342, 2014.
- [21] M. M. Bakr, M. M. Al-Ankily, S. M. Shogaa, and M. Shamel, "Attenuating Effect of Vitamin E against Silver Nano Particles Toxicity in Submandibular Salivary Glands," *Bioengineering*, vol. 8, no. 12, p. 219, 2021.
- [22] A. Moradi, N. Ziamajidi, A. Ghafourikhoshroshahi, and R. Abbaslipourkabir, "Effects of vitamin A and vitamin E on attenuation of titanium dioxide nanoparticles-induced toxicity in the liver of male Wistar rats," *Molecular biology reports*, vol. 46, no. 3, pp. 2919-2932, 2019.
- [23] Y. M. Shotop and I. N. Al-Suwiti, "The possible role of vitamins E and C in reducing the toxicity of copper nanoparticles in the kidney and liver of the rats (*Rattus norvegicus*)," *Journal of King Saud University-Science*, vol. 33, no. 2, p. 101357, 2021.
- [24] H. N. G. El-Hak, E. E. ELaraby, A. K. Hassan, and O. A. Abbas, "Study of the toxic effect and safety of vitamin E supplement in male albino rats after 30 days of repeated treatment," *Heliyon*, vol. 5, no. 10, p. e02645, 2019.
- [25] A. M. Mohammad, S. M. A. Ridha, and T. H. Mubarak, "Dielectric properties of Cr-substituted cobalt ferrite nanoparticles synthesis by citrate-gel auto combustion method," *Int. J. Appl. Eng. Res.*, vol. 13, no. 8, pp. 6026-6035, 2018.
- [26] M. Gómez, D. J. Sánchez, J. M. Llobet, J. Corbella, and J. Domingo, "The effect of age on aluminum retention in rats," *Toxicology*, vol. 116, no. 1-3, pp. 1-8, 1997.
- [27] A. Mohammada, H. A. Al-Jafa, H. S. Ahmeda, M. Mohammedb, and Z. Khodairc, "Structural and morphological studies of ZnO nanostructures," *JOURNAL OF OVONIC RESEARCH*, vol. 18, no. 3, pp. 443-452, 2022.
- [28] S. H. Jaafar *et al.*, "Influence of Calcination Temperature on Crystal Growth and Optical Characteristics of Eu³⁺ Doped ZnO/Zn₂SiO₄ Composites Fabricated via Simple Thermal Treatment Method," *Crystals*, vol. 11, no. 2, p. 115, 2021.
- [29] A. Mohammad, M. Mohammed, and L. Hussein, "Structural, Magnetic And Optical Properties Of Co_{0.5}Ni_{0.5}Fe₂O₄ Nanoparticles Synthesized By Sol-Gel Auto Combustion Method," *Digest Journal Of Nanomaterials And Biostructures*, vol. 15, no. 1, pp. 231-241, 2020.
- [30] D. Raoufi, "Synthesis and microstructural properties of ZnO nanoparticles prepared by precipitation method," *Renewable Energy*, vol. 50, pp. 932-937, 2013.
- [31] N. Asare *et al.*, "Cytotoxic and genotoxic effects of silver nanoparticles in testicular cells," *Toxicology*, vol. 291, no. 1-3, pp. 65-72, 2012.
- [32] T. S. Hauck, R. E. Anderson, H. C. Fischer, S. Newbigging, and W. C. Chan, "In vivo quantum-dot toxicity assessment," *Small*, vol. 6, no. 1, pp. 138-144, 2010.
- [33] L. Espinosa-Cristobal *et al.*, "Toxicity, distribution, and accumulation of silver nanoparticles in Wistar rats," *Journal of nanoparticle research*, vol. 15, no. 6, pp. 1-12, 2013.
- [34] N. Hadrup and H. R. Lam, "Oral toxicity of silver ions, silver nanoparticles and colloidal silver-a review," *Regulatory Toxicology and Pharmacology*, vol. 68, no. 1, pp. 1-7, 2014.
- [35] D. R. Dufour, J. A. Lott, F. S. Nolte, D. R. Gretch, R. S. Koff, and L. B. Seeff, "Diagnosis and monitoring of hepatic injury. I. Performance characteristics of laboratory tests," *Clinical chemistry*, vol. 46, no. 12, pp. 2027-2049, 2000.
- [36] C. E. Ophardt, "Virtual chembook," *Elmhurst College*, pp. 121-125, 2003.
- [37] G.-Y. Liou and P. Storz, "Reactive oxygen species in cancer," *Free radical research*, vol. 44, no. 5, pp. 479-496, 2010.
- [38] C. Mylonas and D. Kouretas, "Lipid peroxidation and tissue damage," *In Vivo (Athens, Greece)*, vol. 13, no. 3, pp. 295-309, 1999.
- [39] M. Kumari *et al.*, "Repeated oral dose toxicity of iron oxide nanoparticles: biochemical and histopathological alterations in different tissues of rats," *Journal of nanoscience and nanotechnology*, vol. 12, no. 3, pp. 2149-2159, 2012.
- [40] F. Zhao, Y. Zhao, Y. Liu, X. Chang, C. Chen, and Y. Zhao, "Cellular uptake, intracellular trafficking, and cytotoxicity of nanomaterials," *small*, vol. 7, no. 10, pp. 1322-1337, 2011.
- [41] O. B. Nnamdi, J. Nyebuchi, A. O. Collins, and Z. L. Udu, "Effects of Vitamin E on Chronic Haematotoxicity of Paraquat Exposed Male Albino Rats (*Rattus norvegicus*)." 2021.
- [42] R. Saravanan and V. Pugalendi, "Impact of ursolic acid on chronic ethanol-induced oxidative stress in the rat heart," *Pharmacological Reports*, vol. 58, no. 1, p. 41, 2006.
- [43] E. J. Simon, C. S. Gross, and A. T. Milhorat, "The metabolism of vitamin E. 1. The absorption and excretion of d- α -tocopherol-5-methyl-C₁₄-succinate," *Journal of Biological Chemistry*, vol. 221, pp. 797-805, 1956.
- [44] J. Abilés *et al.*, "Oxidative stress is increased in critically ill patients according to antioxidant vitamins intake, independent of severity: a cohort study," *Critical care*, vol. 10, no. 5, pp. 1-9, 2006.
- [45] M. Mayer, "Association of serum bilirubin concentration with risk of coronary artery disease," *Clinical chemistry*, vol. 46, no. 11, pp. 1723-1727, 2000.
- [46] F. Dahdouh, A. Salah, R. Mohamed, and K. Zine, "Effect of the joint supplementation of vitamin c and vitamin e on nickel heamatotoxicity and nephrotoxicity in male swiss albino mice," *Int. J. Pharm. Pharm. Sci.*, vol. 8, no. 6, pp. 234-239, 2016.
- [47] R. Yanardag, O. Ozsoy-Sacan, S. Ozdil, and S. Bolkent, "Combined effects of vitamin C, vitamin E, and sodium selenate supplementation on absolute ethanol-induced injury in various organs of rats," *International journal of toxicology*, vol. 26, no. 6, pp. 513-523, 2007.